

DENTSPLY
RAINTREE ESSIX

IPR

INTERPROXIMAL REDUCTION

Technical Guide

Contents

■ Introduction to IPR	5
Historical Perspectives.....	5
Basics of IPR.....	6
Indications and Contraindications.....	7
IPR Methods.....	9
Avoiding Potential Complications.....	10
■ Treatment Planning	13
Overview.....	13
Bolton Analysis.....	14
Staging IPR.....	15
Assessing the Available Space.....	15
Measuring the Available Space.....	16
Procedural Considerations when Performing IPR.....	23
The Use of Elastomeric Separators.....	24
■ Manual Instrumentation	29
Options and Considerations.....	29
Step-By-Step Manual IPR:Method 1.....	30
Step-By-Step Manual IPR:Method 2.....	32
■ Mechanical Instrumentation	35
Options and Considerations.....	35
Step-By-Step: Slow-Speed Contra-Angle Handpiece with Files.....	36
Step-By-Step: Straight Handpiece with Discs.....	39
High-Speed Handpiece with Burs.....	43
Step-By-Step Cosmetic Tooth Recontouring (ARS).....	43
■ Cases & Tips For Success	49
Cases.....	49
Tips for Successful IPR Treatment Planning.....	51
Tips for Successful IPR Execution.....	51
■ Glossary of Terms	53
■ References & Acknowledgments	57



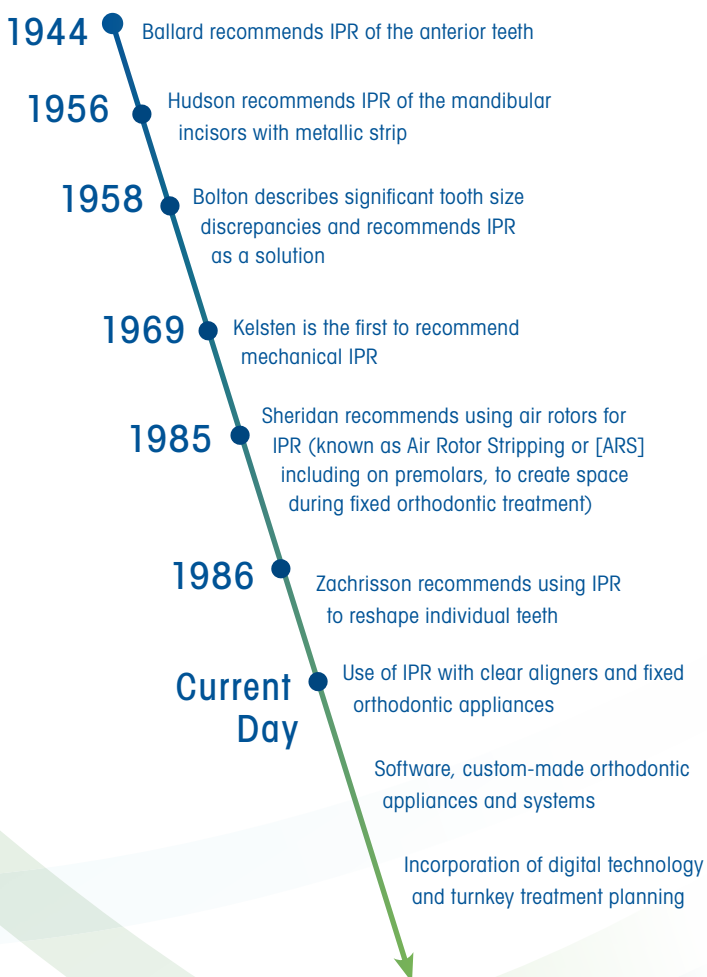
Introduction to IPR

Historical Perspectives

Interproximal reduction (IPR) involves the selective removal of enamel proximally to create space for tooth movement, a technique that was first introduced in the 1940s by Ballard for use on anterior teeth. 'Natural slenderization' had, however, been described by GV Black at the beginning of the 20th century. This concept was later echoed in 1954 when Begg described the natural interproximal abrasion and tooth movement that occurred in Stone Age man as a result of a primitive, rough diet.

IPR techniques changed significantly following the research and recommendations made by Dr. Jack Sheridan in 1985, which included the concept that premolars and molars could also be reduced on their mesial and distal surfaces. Subsequent developments by many researchers led to the techniques and protocols used today for IPR (also known as slenderization or cosmetic tooth recontouring).

IPR can be performed in conjunction with traditional orthodontics or clear aligners, with treatment planned by the clinician or, in some cases, through lab services that utilize digital technology.

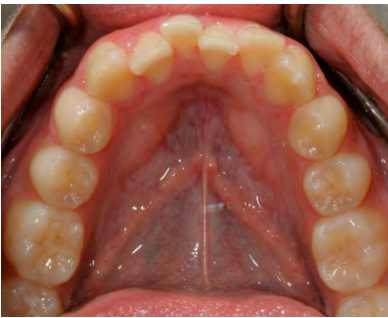

Basics of IPR

IPR is a safe and effective method to create space for orthodontic tooth movement where mild or moderate crowding exists, particularly useful for treating crowding in the anterior segment (the 'social six') and suitable for recontouring individual teeth.

Treating Crowding with IPR

- Where up to 8 mm of space is required within an arch*
- As an adjunct for clear aligners, labial or lingual fixed orthodontic appliances
- In combination with other methods used to create space, (e.g., rapid palatal expansion (RPE), distalization, proclination and extractions).

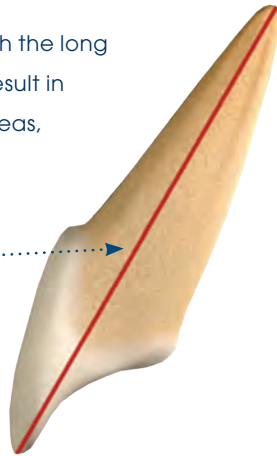


← Mild/moderate crowding case suitable for IPR

Individual Tooth Recontouring with IPR Can be Performed

- When <50% of mesial or distal enamel thickness reduction would be required (maximum amount varies by tooth type)
- When contact points can be accessed
- When IPR can be performed parallel with the long axis of the tooth. Otherwise, IPR would result in excessive removal of enamel in some areas, gouging and the creation of ledges

Red line shows the long axis of the tooth ●.....▶



Advantages of IPR

- May avoid extractions:
 - Less invasive
 - Shorter distances for individual tooth movements
 - Reduces the risk of residual space where extractions would provide more space than is required
- May avoid lengthy arch expansion/distalization/tooth proclination

* Maximum 8 mm posterior, 3 mm maxillary canine-to-canine, 1.4 mm mandibular canine-to-canine

- Acquisition of space can be staged during treatment
- May reduce treatment time
- Opportunity to simultaneously adjust teeth with poor contours or poorly-contoured restorations
- Improves post-treatment stability and stable contact points by flattening contours
- End result may have roots more parallel than with other methods and less relapse

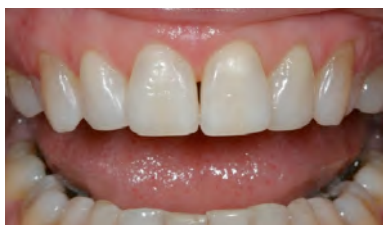Indications & Contraindications For Treatment

Indications

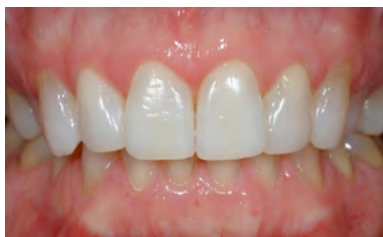IPR offers a proven, relatively noninvasive method for creating space.

Main indications for IPR:

- Crowding of the mandibular or maxillary incisors
- Class I arch-length discrepancies
- Class II minor malocclusions
- Class III minor malocclusions
- Tooth size discrepancy
- Recontouring of teeth
- Presence of poor gingival contours and pre-treatment 'black triangles'
- Correction of the Curve of Spee (the anteroposterior curve determined) by the occlusal alignment of the teeth
- Traumatic occlusion



← Patient with a 'black triangle' and mild crowding

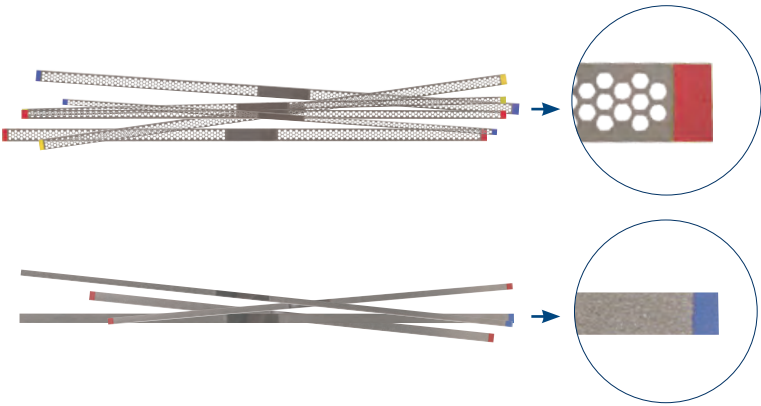
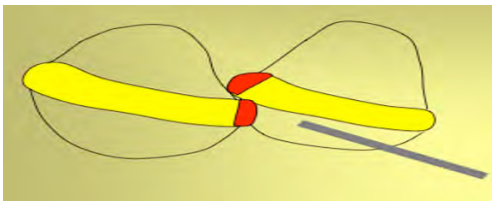


← After IPR and minor tooth movement

Contraindications

- Required reduction exceeds the recommended limit per arch or tooth type
- Hypersensitivity
- Enamel hypoplasia
- Small teeth
- Rectangular-shaped/square teeth, as these require substantial IPR to gain space and produce broad contact surfaces; may also cause food impaction and reduced interseptal bone
- Rotated teeth that preclude proper access to the contact area even with the use of separators
- Large pulp chambers (young patients)
- Major crowding if in the absence of extractions/distalization/other space-gaining methods
- Prior IPR, if additional IPR would exceed the recommended limits for removal of tooth structure

Rotated, overlapping teeth preclude IPR, until derotated or unless using separators can create access for IPR.



Only handheld strips are recommended to break contacts with overlapping teeth to avoid damaging the enamel. Although minor overlap may not make use of thin burs physically impossible, their use may cause damage to the adjacent enamel and is not recommended.

IPR should not be performed if patients (or parents/legal guardians) have not signed an Informed Consent Form confirming acceptance of the recommended treatment.

IPR Methods

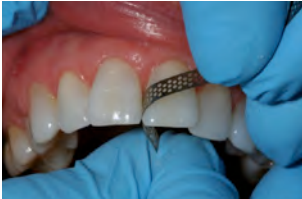IPR may be performed manually or mechanically.

Manual options include:

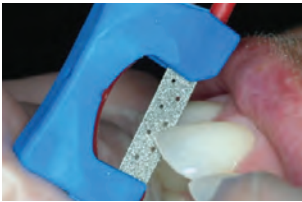
1. Handheld strips
2. Files used with manual holder

Mechanical options include:

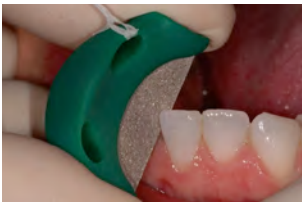3. Files used in an air-driven contra-angle handpieces
4. Discs mounted on a straight slow-speed handpiece (anterior use only)
5. Burs mounted in a high-speed handpiece (Air Rotor Stripping or ARS)



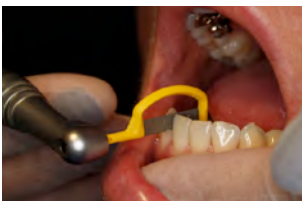1. Use of handheld IPR strips



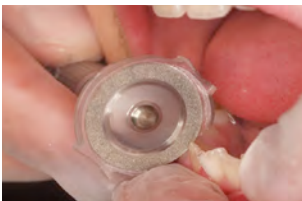2. File used with manual holder



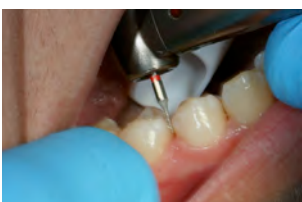3. File used in air-driven
contra-angle handpiece



4. Disc with plastic guard
used in straight slow-speed
handpiece



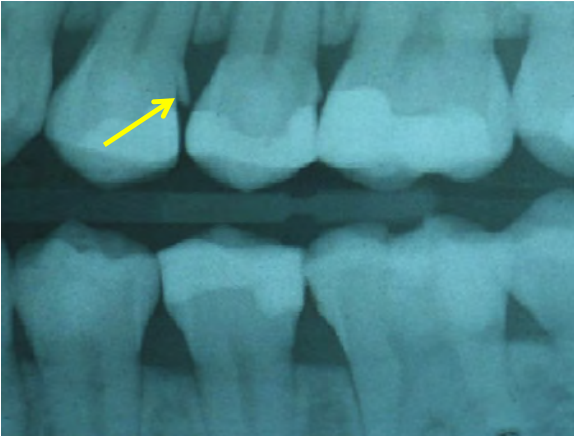
5. Bur used in high-speed
handpiece



Avoiding Potential Complications

Enamel Ledges

Enamel ledges are the result of tooth gouging during IPR and then require use of a bonded resin for resolution. Ledging is avoided by taking care to perform IPR parallel with the long axis (versus vertically and perpendicular to the occlusal surface). Ledging is unlikely to occur with the use of manual strips.



← Enamel ledging on radiograph

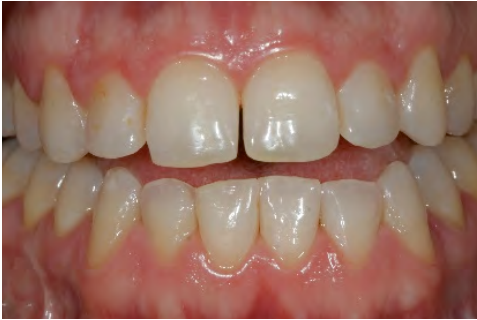Black Triangles

Black triangles result in poor esthetics. They can occur if IPR is performed on teeth with inadequate distance between the interproximal contact point and the upper margin of the bone crest. The recommended distance is 4.5 mm to 5 mm.

Black triangles can also occur when IPR is performed on triangular-shaped teeth, which have a relatively long distance from the bone crest to the interproximal contact point. Once this distance is >5 mm, the interproximal papilla may be absent, resulting in a black triangle.

Poor Contouring

Flattening the contact and not rounding it off after IPR can cause teeth to appear square/stubby.



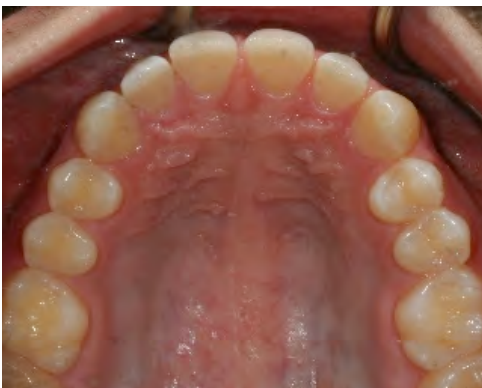← Poor contouring and 'square/flat appearance'

Soft Tissue Injury

Care must be taken to protect the lips, tongue and gingivae during IPR – for example with a mouth mirror, and in the case of discs by using a protective shield.

Excessive Interproximal Reduction

If too much enamel is removed, residual space at the end of treatment can result in potential esthetic problems and food impaction (and possibly necessitate additional orthodontic treatment or cosmetic restorations).



← Residual space



Treatment Planning

Overview

Treatment planning includes:

- Full medical and dental history
- Full examination, radiographs and accurate impressions for study models
- Measurements and assessments as described below

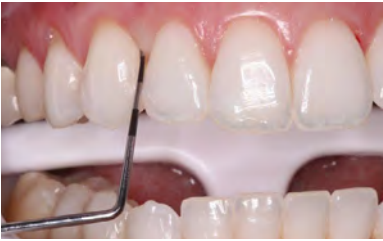Accurate Measurement & Assessment Must be Performed

The following measurements and assessments are required during treatment planning:

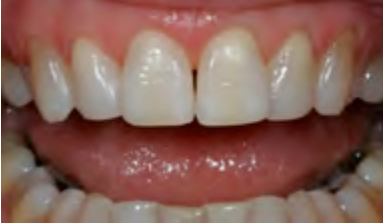- Inter-arch relationship: position of the maxillary and mandibular arches relative to each other
- Relationship between the upper and lower incisors
- Width of the teeth at their broadest point
- Width of arches
- Width of roots relative to the widths of the crowns of the teeth
- Distance between the bone crest and contact points:
 - Performed by sounding the bone from the base of the contact point – lengths of 4.5 mm to 5 mm will allow the papillae to fill the spaces. Larger distances usually result in incomplete papillary fill causing black triangles and poor esthetics
- Thickness of the enamel
 - Observed by assessment of radiographs
 - Must consider tooth type, as this influences the thickness of the enamel
- Tooth size discrepancies, using the Bolton Analysis

In addition, the following must be assessed:

- Shape of teeth: Square/rectangular/triangular/barrel-shaped
 - Triangular teeth often present with black triangles; these can be improved upon by IPR, making these teeth potentially good candidates
 - Barrel-shaped and triangular teeth have thicker enamel, therefore more enamel available for IPR
- Presence of parafunctional habits



← Bone sounding



← Black triangle pre-treatment

Note: The presence of parafunctional habits such as lip chewing, digit sucking, nail biting or tongue thrusting must be assessed and if present these habits should be resolved prior to starting treatment.

Bolton Analysis

The Bolton Analysis is used to identify tooth size discrepancies. 'Oversized' teeth can be good candidates for IPR as this corrects the discrepancy and creates the space required for tooth movement. Therefore, identifying these discrepancies during treatment planning is important. In addition, consider recontouring over-dimensioned restorations and performing IPR on proximal restoration surfaces (as this preserves enamel). Either the Anterior Bolton Index (ABI) or the Overall Bolton Index (OBI) (also known as the First-Molar-to-First-Molar Bolton Index) may be used.

The Anterior Bolton Index (ABI)

The ABI is obtained by adding the mesiodistal width of the mandibular canines and incisors and dividing this by the mesiodistal total of the maxillary canines and incisors. The ideal ABI ratio is 77.2 ± 1.65 , which provides for a cuspid Class I relationship.

The Overall Bolton Index (OBI)

The OBI is obtained by adding the mesiodistal width of the mandibular teeth from first molar to first molar, and dividing this by the mesiodistal total size of the maxillary first molar to first molar. The ideal OBI ratio is 91.3 ± 1.91 , which provides for a molar Class I relationship.

Deviations from the ideal ABI or OBI ratio indicate a tooth size discrepancy that may be treated using IPR alone or in combination with other space-creating methods.

Staging IPR

Staging IPR is important to consider when treatment planning, starting with the tooth/teeth that require(s) the most adjustment. If teeth are rotated or severely overlapped, sequentially derotating them or removing some overlap may make it possible to perform IPR on adjacent surfaces to obtain the required space on the true proximal surfaces (e.g., rather than removing enamel from a buccal surface which is temporarily proximally placed because of the rotation).

Staged IPR should be treatment planned to:

- Improve access to proximal contacts
- Avoid IPR on inappropriate surfaces
- Perform IPR when suitable access to the mesial/distal surfaces is possible
- Avoid iatrogenic damage while performing IPR adjacent to severely overlapped/rotated teeth
- Avoid creating excess space by removing too much in one phase
 - Excess space can result in aesthetic problems and areas subject to food impaction

The treatment plan must carefully consider which teeth will receive IPR, and staging of IPR. ALL factors discussed above must be considered including: Inter-arch relationship, tooth and arch width, crown-root width ratio, bone crest and contact point positions, shape of teeth, enamel thickness, toothsize discrepancy and the presence of black triangles.

Assessing the Available Space & Space Required for Tooth Movement

A space analysis should be performed using calipers on the patient's beginning stone model. The amount of space (in millimeters) needed to resolve the crowding should be determined and written in the treatment plan. Depending upon the malposition of individual target tooth, the measurements required for space analysis may be taken from the buccal, lingual or incisal directions.

The space analysis begins by measuring the width of each target tooth at its widest point. These measurements are then added together for the total width (TW) of the target teeth.

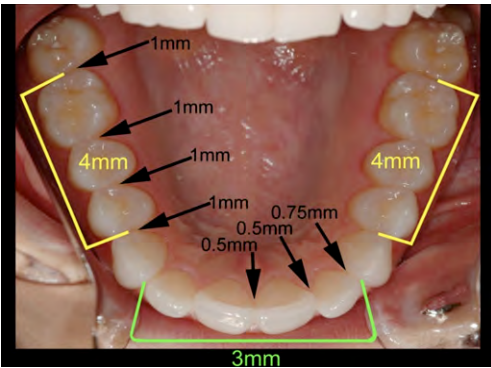
The available space for each target tooth is then determined by measuring the distance between each adjacent tooth in relation to each target tooth. These measurements are then added together for the actual space (AS) of the target teeth.

The difference between the total width and the actual space available represents the amount of space required (SR). Knowing how much enamel may be safely removed from a tooth is crucial to the success of IPR.

The clinician may safely remove 0.5 mm of enamel from all proximal surfaces except the incisors. For esthetics and safety, enamel reduction of incisors should be limited to 0.25 mm at each proximal surface. This means that a total of 3 mm of enamel can be removed from the mesial surface of one cuspid to the mesial surface of the opposite cuspid.

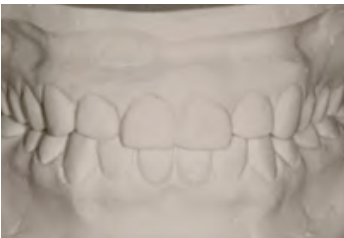If second molars are present, then 4 mm of enamel can be removed from each side of an arch – (i.e., from the distal surface of the cuspid to the mesial surface of the second molar) – for a maximum safe full arch space creation of 11 mm.

Obviously, less space can be obtained if there are missing teeth and the extraction space has (partially) closed, or if IPR was performed during a prior course of treatment and there is therefore less available enamel.

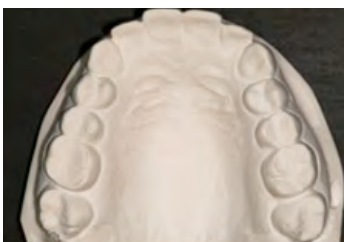

Measuring the Available Space & Determining Where to Begin

Example 1



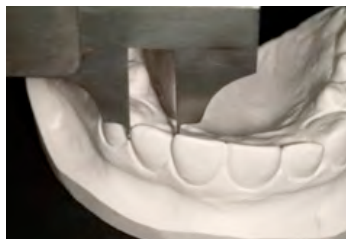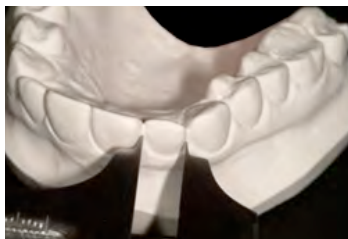← Upper and lower arches occluded to show that upper and lower midlines are even



← **Upper Arch:** Looking at the occlusal view, it is apparent that tooth #7 and tooth #10 are out of alignment

The following two images illustrate how to obtain the measurements for the total width (TW) of the target teeth.

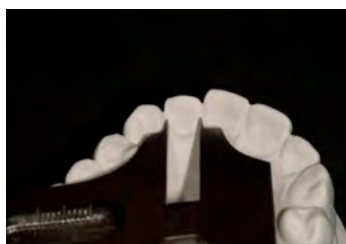
TW for tooth #7 measured 7 mm and TW for tooth #10 also measured 7 mm, for a TW of 14 mm.



Next, measurements are obtained for the actual space (AS) available for the target teeth, as shown here: AS for tooth # 7 measured 6.3 mm while AS for tooth #10 measured only 5.5 mm, for a total AS of 11.8 mm. Therefore, the total amount of space required (SR) for the upper arch is:

$$TW - AS = SR$$

$$14 \text{ mm} - 11.8 \text{ mm} = 2.2 \text{ mm}$$



Although there are many acceptable teeth to begin IPR in this case, maintaining esthetics and symmetry, including the midlines, should be the number one priority. Therefore, the starting point on the right side will be the distal surface of tooth #6. The calculations for IPR for the right side are as follows:

$$\begin{array}{r} 0.2 \text{ mm IPR distal of tooth \#6} \\ + 0.5 \text{ mm IPR mesial of tooth \#6} \\ \hline = 0.7 \text{ mm total IPR} \end{array}$$

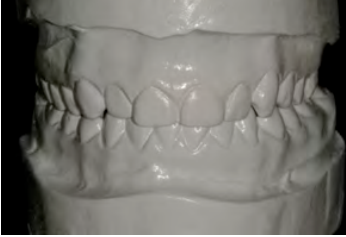Tooth #6 will be distalized into the 0.2 mm space created with the initial IPR prior to reducing the mesial of the same tooth. This will provide the 0.7 mm of space that tooth #7 requires for proper alignment in the arch. In order to properly align #10 into the arch, 1.5 mm of space must be created. The starting point for IPR on the left side will be the mesial surface of tooth #12. The calculations are as follows:

$$\begin{array}{r} 0.5 \text{ mm IPR mesial of tooth \#12} \\ 0.5 \text{ mm IPR distal of tooth \#11} \\ + 0.5 \text{ mm IPR mesial of tooth \#11} \\ \hline = 1.5 \text{ mm total IPR} \end{array}$$

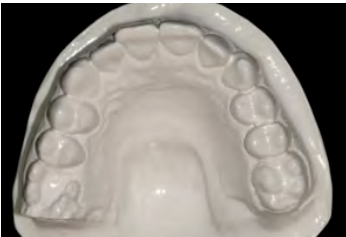Tooth #11 will be distalized into the 1 mm space created with the initial IPR prior to reducing the mesial of #11. This will provide the 1.5 mm necessary to properly align #10.

Example 2

Upper and lower arches occluded to show that the lower midline is approximately 1mm left of the upper midline.

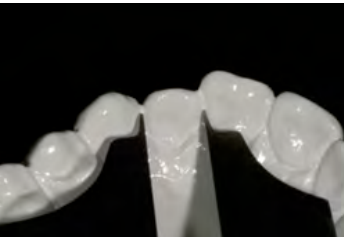

← The upper midline is correct when looking at the patient's face. Therefore, it is desirable to shift the lower midline to the right to create symmetry. This is a more complex case in that there is more crowding and more target teeth than the previous cases. Upper and lower arches are in need of alignment.



← **Upper Arch:** Although the patient's chief complaint was regarding the right and left laterals (#7 and #10), the occlusal view of her model indicated the case would have a more esthetic result if the upper right central (#8) and the upper left cuspid (#11) were also included in the treatment.

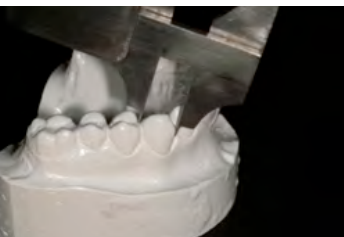The following three images illustrate how to obtain the measurements for the **total width (TW) of the target teeth**. The individual measurements for TW were as follows:



← Tooth #7 = 6.5 mm



← Tooth #8 = 8.7 mm

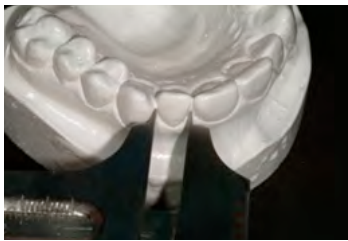

← Tooth #10 = 6.5 mm; #11 = 8.2 mm

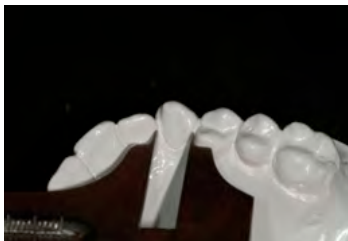Next, measurements are obtained for the actual space (AS) available for the target teeth, as follows:



← Tooth #7 = 6.1 mm



← Tooth #8 = 7 mm



← Tooth #10 = 6.1 mm; #11 = 6.6 mm

Therefore, the amount of space required (SR) for the upper arch is:

$$\begin{aligned} \text{TW} - \text{AS} &= \text{SR} \\ 29.9 \text{ mm} - 25.8 \text{ mm} &= 4.1 \text{ mm} \end{aligned}$$

The starting point of IPR on the right side will be at the mesial surface of tooth #4. The calculation for IPR on the right side is as follows:

$$\begin{aligned} &0.3 \text{ mm IPR mesial of tooth \#4} \\ &0.3 \text{ mm IPR distal of tooth \#5} \\ &0.5 \text{ mm IPR mesial of tooth \#5} \\ &0.5 \text{ mm IPR distal of tooth \#6} \\ &0.5 \text{ mm IPR mesial of tooth \#6} \\ + &0.1 \text{ mm IPR distal of tooth \#8} \\ \hline = &2.1 \text{ mm total IPR} \end{aligned}$$

Tooth #5 will need to be distalized into the 0.6 mm space created with IPR prior to reducing the mesial of tooth #5 and the distal of tooth #6. It should always be ensured that you have tight contacts when distalizing teeth before proceeding to the next area to be addressed with IPR. When #6 is distalized into a tight contact with #5, then proceed to the mesial of tooth #6 with IPR.

The starting point of IPR on the left side will be the mesial surface of tooth #13.
The calculation for CTR is as follows:

0.25 mm IPR mesial of tooth #13
0.25 mm IPR distal of tooth #12
0.5 mm IPR mesial of tooth #12
0.5 mm IPR distal of tooth #11
0.4 mm IPR mesial of tooth #11
+ 0.1 mm IPR distal of tooth #8
= 2.0 mm total IPR

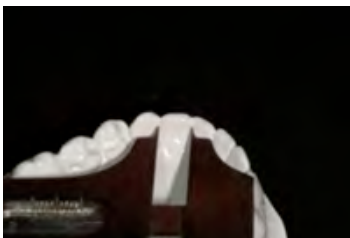No reduction of the upper laterals will be performed because they are already narrow and if reduced could compromise the esthetic outcome. Tooth #8 and #9 are re-contoured by the same amount, and only on the distal surfaces in order to maintain the midline position.



← **Lower Arch:** The occlusal view of the lower model shows that the target teeth should be left canine (#22) through right canine (#27). However, the patient has no desire to straighten the canines; They only want to have the four incisors straightened.

Obtaining the Space Required

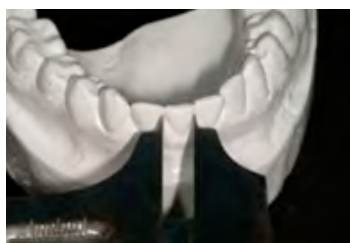The four images below illustrate how to obtain the measurements for the total width (TW) of the target teeth. The individual measurements for TW were as follows:



Tooth #26 = 5.9 mm



Tooth #23 = 5.9 mm

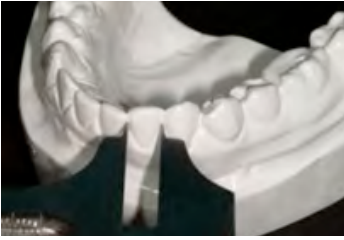

Tooth #24 = 5.1 mm

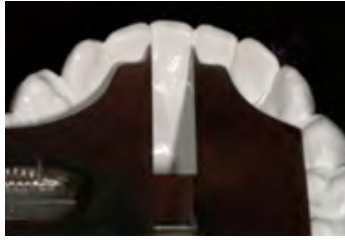

Tooth #25 = 5.1 mm

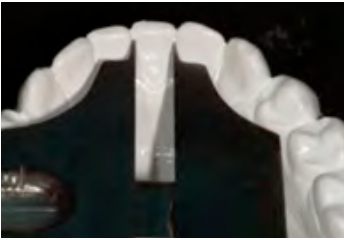Next, measurements are obtained for the actual space (AS) available for the target teeth, as follows:



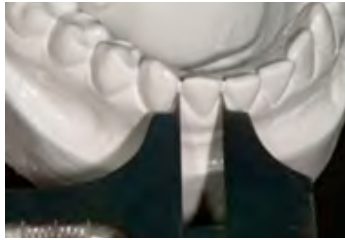Tooth #23 = 5.1 mm



Tooth #24 = 4.3 mm



Tooth #25 = 5.1 mm



Tooth #26 = 5.7 mm

Therefore, the amount of space required (SR) for the lower arch target is:

$$TW - AS = SR$$

$$22 \text{ mm} - 20.2 \text{ mm} = 1.8 \text{ mm}$$

The crowding on the left side (1.6 mm) appears to be more severe than on the right side (0.2 mm). However, the need to shift the lower midline to the right means that 1.2 mm of space needs to be created on the right side and only 0.6 mm of space on the left side. Although it is not a requirement that the upper and lower midlines are even, the esthetic outcome will be better if they are.

The starting point of IPR on the left side will be at the mesial surface of tooth #22. The calculation for IPR on the left side is as follows:

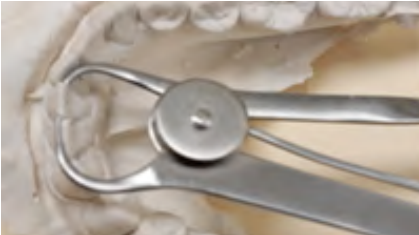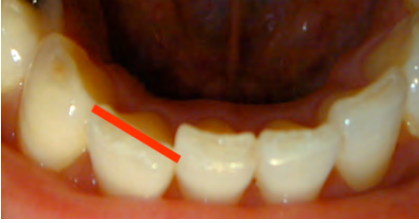$$\begin{aligned} &0.2 \text{ mm IPR mesial of tooth \#22} \\ &0.2 \text{ mm IPR distal of tooth \#23} \\ &+ 0.2 \text{ mm IPR mesial of tooth \#23} \\ &= 0.6 \text{ mm total IPR} \end{aligned}$$

The starting point of IPR on the right side will be at the mesial surface of tooth #27. The calculation for IPR on the left side is as follows:

$$\begin{aligned} &0.5 \text{ mm IPR mesial of tooth \#27} \\ &0.25 \text{ mm IPR distal of tooth \#26} \\ &0.25 \text{ mm IPR distal of tooth \#26} \\ &0.1 \text{ mm IPR distal of tooth \#25} \\ &+ 0.1 \text{ mm IPR mesial of tooth \#25} \\ &= 1.2 \text{ mm total IPR} \end{aligned}$$

IPR was performed at the starting point on each side at the same time.

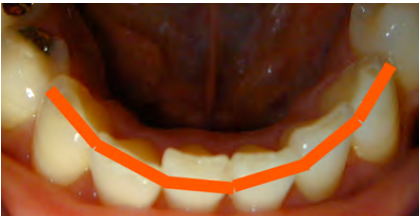Measuring the Available Space: Alternative Methods



Measuring incisal width in vivo

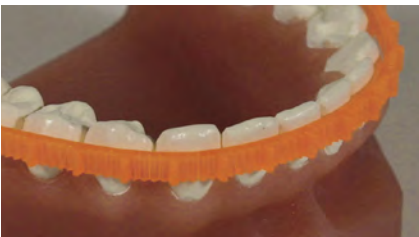← Other methods for measuring the teeth and arch width include using a gauge in vivo. The teeth are measured at their widest point.

The tooth measurements are then summed together to obtain the total width of all teeth. Any space available adjacent to or near target teeth should be noted separately.



Measuring canine-to-canine

← The arch width can be measured canine-to-canine where only the social six are involved or second molar-to-second molar where the full arch is involved, using an arch gauge.



Measuring second molar-to-second molar



← Alternatively, floss or a ribbon can be used to determine the lengths and then measured against an orthodontic ruler. Next, the arch length difference (ALD) and space requirements can be assessed in the same manner as before.

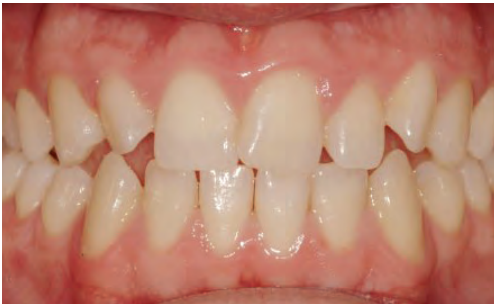Procedural Considerations when Performing IPR

IPR procedural considerations include the shape and position of teeth being considered candidates for IPR, treatment staging, the use of local anesthesia, IPR method to be used, periodontal and caries status.

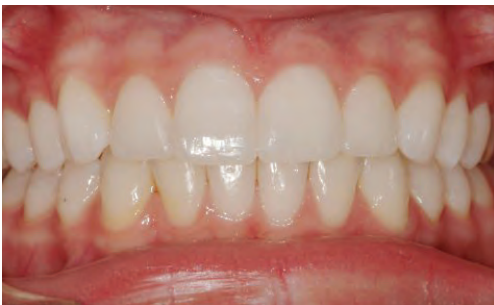Dental and Soft Tissue Considerations

- Symmetrical midlines should be preserved
- Over-reduced laterals may resemble peg laterals
- IPR should result in a contact point aligned with the vertex of the papilla
- Soft tissue must be protected during IPR
 - Avoid creating wide interproximal spaces – these are a risk factor for intrabony defects
- Enamel is generally thicker on the distal surface of the tooth than on the mesial surface; this needs to be considered with respect to the location of IPR

Based on studies, periodontal status has not been shown to be compromised following IPR.



Asymmetrical midline



Symmetrical midline

Manual vs. Mechanical IPR

- Manual IPR is less likely to result in soft tissue injury
- Manual IPR is more time-consuming than mechanical IPR
- Mechanical devices require more intraoral space for access
 - The angle of approach during IPR is critical to the contact points and tooth contours
 - Unless performed along the long axis of the tooth, IPR can result in poor contours and open contacts
- Contra-angle handpieces are suitable for the anterior and posterior regions
- Straight handpieces with rotary discs are suitable only for the anterior region due to limited space and access, and a disc guard should always be used to protect soft tissues. Clear disc guards improve visibility vs. metal guards
- Only strips are recommended to break contacts with overlapping teeth to avoid damage to enamel

Caries Susceptibility

There is no evidence that IPR is associated with an increase in proximal caries lesions. Abraded enamel has surface porosities and therefore remineralizes more rapidly than nonabraded enamel, becoming more resistant to demineralization. Fluoride gel is recommended to encourage remineralization.

The Use of Elastomeric Separators

Elastomeric separators serve to:

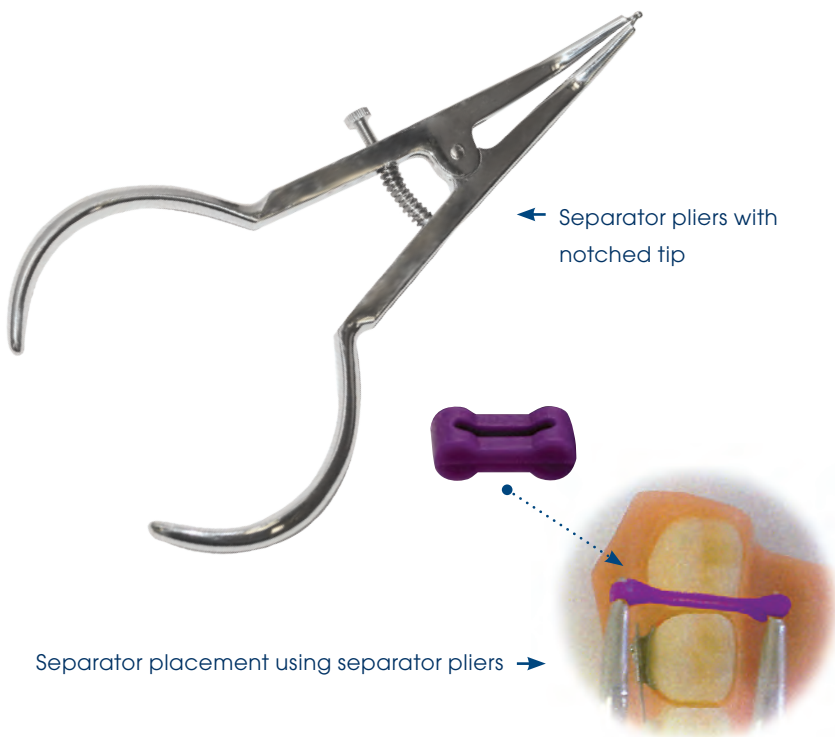
- Create temporary space interproximally to enable initial IPR
- Improve access where tight or overlapped contacts are present
- Help avoid iatrogenic damage to dental hard tissue and gingivae

These should be used prior to mechanical IPR (unless space is already present for instrumentation), and may also be used prior to manual IPR.

Separators or elastomeric rings. They are available as:

- Thin anterior separators
- Posterior separators
- Loose radiopaque separators

Separator pliers should be used when placing or removing separators. These pliers have a notched tip that helps prevent the separator from slipping during manipulation, helping to avoid potential ingestion/inhalation/misplacement of separators. During removal, an explorer may be used as an alternative.

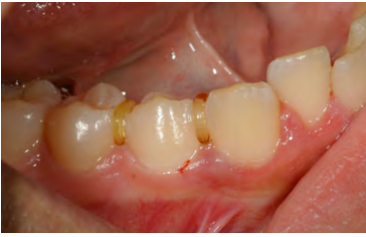

Alternative Method: Loop floss through the separator. Then, while holding the floss at both ends, push the separator into position and then remove the floss from the separator.

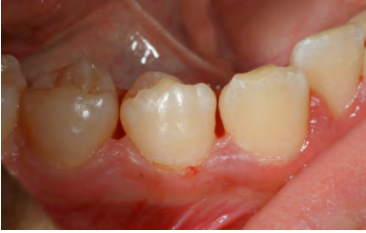Prior to IPR, separators should remain in place for:

- 2 to 4 days in the anterior region
- 1 week in the posterior region

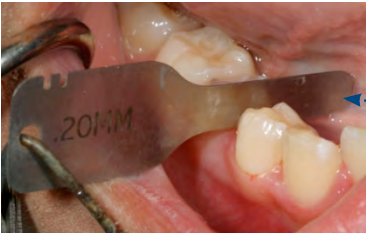Prior to performing IPR, the separators are removed and the space created by them is measured. **This is critical as the space created is only temporary and rebounds once the separators have been removed.** If this space is not measured and considered, the amount of space that must be created using IPR based on the treatment plan will be underestimated. After the separators have been removed, the procedure and measurement during IPR are the same regardless of which devices are used to perform IPR.



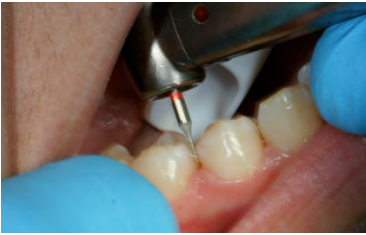← Separators 1 week after placement



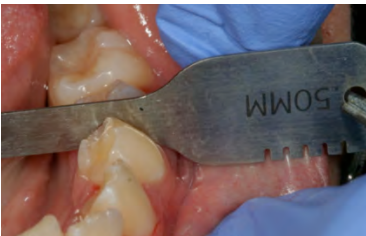← Step 1: Remove the separators



← Step 2: Measure the space created by the separators



← Step 3: Begin IPR and perform in stages

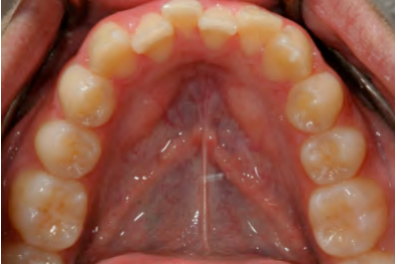

← Step 4: Measuring space created

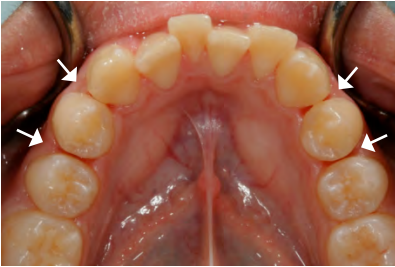Measuring the space created periodically during IPR helps avoid creating too much space.

NOTE: The Measured space will INCLUDE the space created by the separators, which must be subtracted out to determine the space created by IPR.

After sufficient space has been created, the proximal contours are finished and polished.



← Example pre-IPR



← Following IPR on bicuspid interproximal surfaces

Topical Anesthesia

IPR elicits no dental discomfort, however separator placement can cause discomfort and the gingivae may be impinged upon during IPR. Topical anesthetic will relieve IPR-related discomfort.

Options include:

- 2.5% Benzocaine gel
- Lidocaine gel
- Hurracaine gel

For patients who are extra sensitive, local anesthesia may be indicated.



Manual Instrumentation

Options and Considerations

Options include perforated mesh strips that increase visibility and help to remove debris during IPR.

Solid diamond strips can be used manually.

Using IPR files that do not have a cutting edge helps to avoid the introduction of defects and poor contours during IPR.

Serrated files (or saws) are used to break contact points if the IPR files do not have a cutting edge. Then single-sided or double-sided IPR files are used (single-sided files enable IPR on one proximal surface at a time).

Files that are color-coded based on thicknesses size allow easy identification and process standardization.

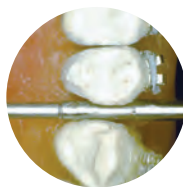
Regardless of the method used to obtain space, gauges are required for measuring the space created. Performing IPR in gradual, sequential steps is essential for good clinical outcomes.

In selecting grit-impregnated files, consideration should be given to design and advantageous features:

- High-precision products
- Perforated files improve visibility and prevent clogging while reducing the enamel
- Use of a serrated contact point saw (on enamel or restorative materials) to break contact points
- Selection of double-sided and left/right (L/R) single-sided files with a wide range of thicknesses (e.g., SpaceFile® Files range from 0.14 mm to 0.490 mm for double-sided files and 0.123 mm to 0.290 mm for single-sided files)
- Files color-coded by thickness, for ease-of-use
- Finishing and polishing files to provide a smooth, well-contoured surface after IPR
- Ability to use the same file either in a removable grip or manually
- Use of autoclavable components for infection control



IPR Gauges are used to measure space



For larger spaces, an ARS Gauge may be used

Step-By-Step Manual IPR: Method 1

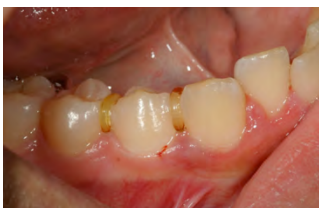
Required Tools and Supplies

- If needed to create access: separators, and separator pliers or floss for placement
- IPR Gauge Set to measure space created in fine increments
- Grip (optional)
- Serrated contact point saw to break contact points
- Double-sided and single-sided files of different thicknesses (e.g., SpaceFile® Files range from 0.14 mm to 0.490 mm for double-sided files and 0.123 mm to 0.290 mm for single-sided files)
- Finishing and polishing files

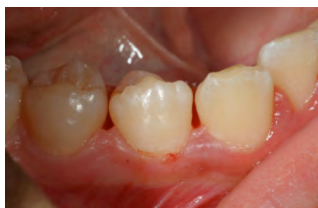Step 1

If separators were used between the teeth where IPR is planned, first remove the separators using Separator Pliers or an explorer.

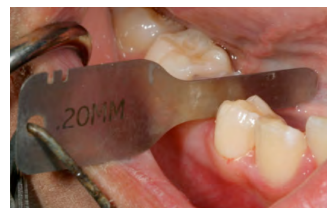Then, measure the amount of space present after removal of the separators, using the IPR Gauge. The gauge size that gives a slight tug in the space indicates the size of the space.



↑
Separators in place for
1 week



↑
Remove the separators



↑
Measure the space created

Step 2

Add the measured amount of space created by the separators to the amount of reduction indicated on the treatment plan for the first phase of IPR. The total amount is the amount that needs to be present at the end of this visit.

For instance:

Total space created by separators = 2 mm

Space required from IPR phase 1 of treatment plan = 2 mm

Total space present at end of phase 1 IPR appointment needs to equal 4 mm

Note: The 2 mm gained by wearing the separators for 1 week is created to make IPR instrumentation easier. The separator-induced space closes rapidly, therefore this amount must NOT be included as 'gained space' for the treatment plan.

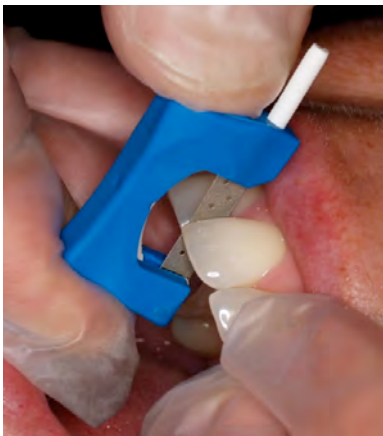Step 3

If needed, break contact points on enamel (or restorations) using the serrated contact point saw →



Step 4

Using a double-sided or L/R single-sided file, initiate IPR in accordance with the treatment plan on where space should be created (mesial or distal surfaces of specific teeth, including adjacent teeth).



Using a double-sided file in a hand grip

A single-sided file is indicated where only one of two adjacent surfaces will be reduced. If differing amounts will be removed from adjacent surfaces, single-sided files should be used to create the planned reduction on one surface and then separately on the adjacent surface for its planned amount of reduction.

Files should be selected based on the amount of crowding, starting with the finest file size that creates resistance when placed between the teeth.

Caution: Only use the first file that creates resistance until it no longer does, then measure the space before proceeding further to avoid creating excess space.

Step 5

Measure the space created using the IPR Gauge. → Repeat Steps 2 & 3 until the planned space has been created (or total of the separator-induced and planned space).



Step 6

Use a finishing strip after completing IPR, then polish the enamel surfaces using a polishing file.

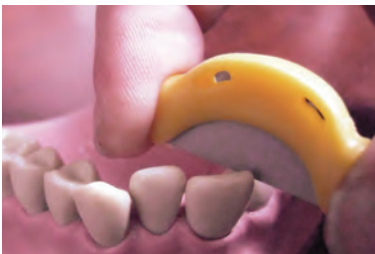
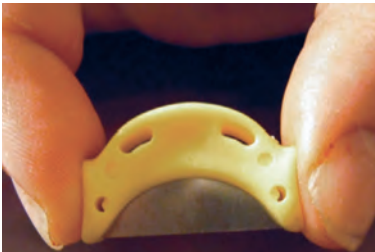Note: Multiple-use files should be discarded if damaged, broken, bent or if the grit appears faded or worn.

Step-By-Step Manual IPR: Method 2

Required Tools and Supplies

- IPR Gauge Set to measure space created in fine increments
- Grip (optional)
- QwikStrips™ of different grit thicknesses
- Finishing and polishing files
- Double-sided and single-sided files of different grit thicknesses (e.g., SpaceFile® Files range from 0.14 mm to 0.490 mm for double-sided files and 0.123 mm to 0.290 mm for single-sided files)

Step 1 • Beginning Phase One



- ← Create the initial opening conservatively, using a single-sided yellow strip gripped between the thumb and forefinger and pass it gently through the contact point. Stop once there is no resistance.

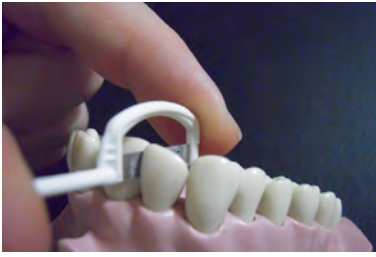The yellow strip is the least coarse and will fit into virtually any contact, even if teeth are tightly overlapped. Since the strips are not end cutting, ledging is avoided. The friction of their abrasive side removes a very fine amount of enamel.

Step 2



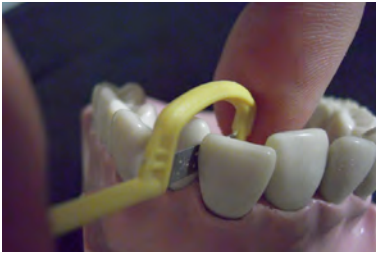- ← Repeat Step 3 with the red strip, then the blue strip and then the green strip. After using these strips in this sequence, the space between the contact points will be < 0.1 mm.

Step 3 • Beginning Phase Two



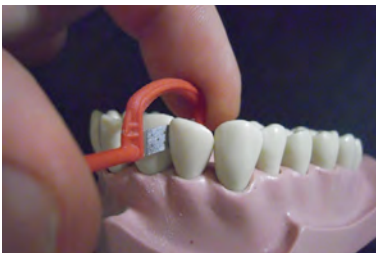- ← Begin by using the white double-sided file gripped between the forefinger and thumb, and gently pass it through the contact. Stop when there is no friction. The space will now measure 0.1 mm.

Step 4



- ← Grip the yellow file between the forefinger and thumb and pass it gently through the contact. Stop when there is no friction. The space will now measure 0.15 mm.

Step 5



- ← Grip the red file and pass it through contact until there is no resistance. Stop when there is no friction. The interproximal space is now an exact 0.2 mm opening.

Step 6

If the desired space is 0.3 mm repeat the above step using the grey file.

Step 7

If the desired space is 0.4 mm, use the green file. This may require a little pressure. In this step only, additional cutting can be accomplished by leaning the green file against the tooth.

Step 8

If still more space is desired, continue with the black and then the blue files to create a 0.5 mm space.

Note: The strips and files will only cut where there is contact between the teeth. It is critical to remember that the strips must be used sequentially for Phase One, and the files must be used sequentially for Phase Two.



Mechanical Instrumentation

[HANDPIECE | ROTARY•DRIVEN]

Options and Considerations

Options for mechanical instrumentation include the use of a slow-speed contra-angle handpiece with files, a slow-speed straight handpiece with discs or a high-speed handpiece with burs (often referred to as 'air rotor stripping' or 'ARS').

Files may be double- or single-sided, with cutting or noncutting edges. Using IPR files with noncutting edges helps to avoid the introduction of defects and poor contours, especially when space is limited. Strips are recommended to break contact with overlapping teeth to avoid damage to enamel.

After breaking the contact point, in the case of slow-speed handpiece instrumentation, the selected single-sided or double-sided IPR files or discs are used. Using single-sided IPR files or discs enables treatment of one proximal surface at a time.

Files that are color-coded based on thicknesses allow easy identification and help to standardize the process.

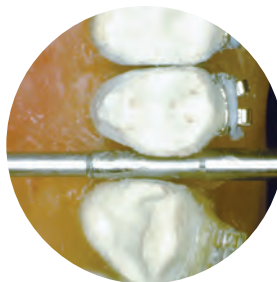
Regardless of the method used to obtain space, gauges are required for measuring the space created.

Performing IPR in gradual, sequential steps is essential for good clinical outcomes.

- High-precision products
- Perforated files improve visibility and prevent clogging while reducing the enamel
- Use of a serrated contact point saw (on enamel or restorative materials) to break contact points
- Selection of double-sided and left/right (L/R) single-sided files with a wide range of thicknesses (e.g., SpaceFile® Files range from 0.14 mm to 0.490 mm for double-sided files and 0.123 mm to 0.290 mm for single-sided files)
- Files color-coded by thickness, for ease-of-use
- Finishing and polishing files to provide a smooth, well-contoured surface after IPR
- Ability to use the same file either in a removable grip or manually
- Use of autoclavable components for infection control



IPR Gauges are used to measure space



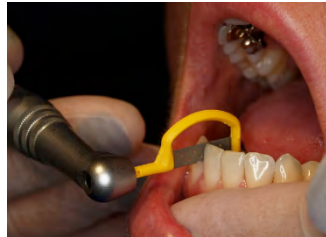For larger spaces, an ARS Gauge may be used

Step-By-Step: Slow-Speed Contra-Angle Handpiece with Files



Using a slow-speed handpiece with files automates IPR, and does not rely on the operator performing the movement.

• Contra-angle handpiece with file



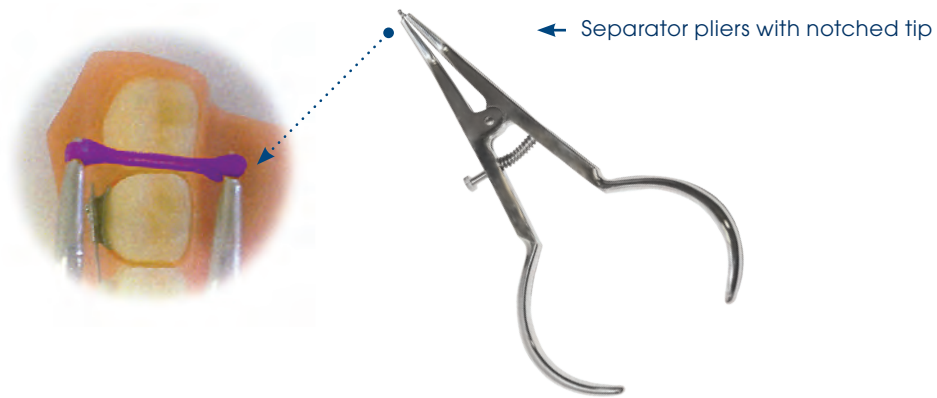
Contra-angle handpiece and file in use

Required Tools and Supplies

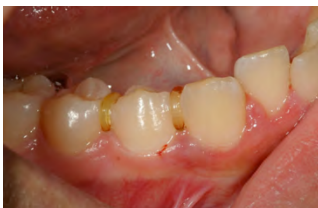- If needed to create access: separators, and separator pliers or floss for placement
- IPR Gauge Set to measure space created in fine increments
- Grip (optional)
- Serrated contact point saw to break contact points
- Double-sided and single-sided files of different grit thicknesses (e.g., SpaceFile® Files range from 0.14 mm to 0.490 mm for double-sided files and 0.123 mm to 0.290 mm for single-sided files)
- Finishing and polishing files
- Contra-angle handpiece and motor

Step 1

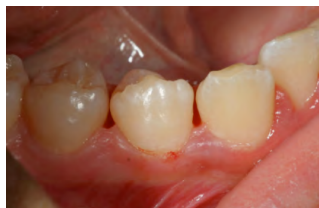If separators were used between the teeth where IPR is planned, first remove the separators using Separator Pliers or an explorer.



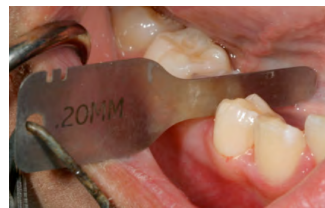Then, measure the amount of space present after removal of the separators, using the IPR Gauge. The gauge size that gives a slight tug in the space indicates the size of the space.



↑
Separators in place for
1 week



↑
Remove the separators



↑
Measure the space created

Step 2

Add the measured amount of space created by the separators to the amount of reduction indicated on the treatment plan for the first phase of IPR. The total amount is the amount that needs to be present at the end of this visit.

For instance:

Total space created by separators = 2 mm

Space required from IPR phase 1 of treatment plan = 2 mm

Total space present at end of phase 1 IPR appointment needs to equal 4 mm

Note : The 2 mm gained by wearing the separators for 1 week is created to make IPR instrumentation easier. The separator-induced space closes rapidly, therefore this amount must NOT be included as 'gained space' for the treatment plan.

Step 3

First open the contact point using an end-cutting serrated interproximal file (serrated contact point saw) or strip that will open the contact.



Step 4

Initiate IPR using a file of the smallest width to avoid binding. Pass the white file gently through the contact. Stop when there is no friction. The space will now measure 0.1 mm.



0.140 mm

Step 5

Grip the yellow file between the forefinger and thumb and pass it gently through the contact. Stop when there is no friction. The space will now measure 0.15 mm.



0.160 mm

Step 6

Grip the red file and pass it through the contact until there is no resistance. Stop when there is no friction. The interproximal space is now an exact 0.2 mm.



0.270 mm

Step 7

If the desired space is 0.3 mm, repeat the above step using the grey file.



0.085 mm

Step 8

If the desired space is 0.4 mm, use the green file.



0.370 mm

Step 9

If still more space is desired, continue with the black and then blue files to create 0.5 mm of space.



0.330 mm

Note: The strips and files will only cut where there is contact between the teeth. When there is no contact between teeth they will not cut. It is critical to remember that the strips must be used sequentially.

Step-By-Step: Straight Handpiece with Discs

IPR discs in mandrels are used in straight slow-speed handpieces. This method is quicker than with manual strips. Discs are available for breaking contacts, enamel stripping, contouring and finishing. **Due to access constraints, this technique is used only in the anterior segment.**

Required Tools and Supplies

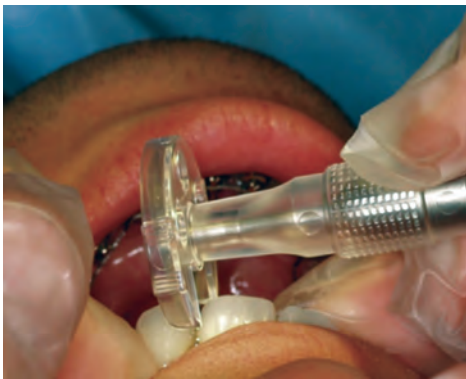- Separators, and separator pliers or floss for separator placement
- IPR Gauge Set
- Slow-speed handpiece
- Double-sided and/or single-sided diamond discs to break contact points and for contouring
- Double-sided discs for anterior IPR
 - Flexible curved discs (0.10 mm thick)
 - Flexible serrated discs (0.20 mm thick)
- Mesh discs for IPR stripping and ultra-fine contouring and shaping
- Snap-on finishing discs
 - Requires a separate mandrel
- Clear adapters for over discs to protect soft tissue

Note: Only handheld strips are recommended to break contacts with overlapping teeth to avoid damage to enamel

Extra care is required with handpiece/rotary instrumentation as this can quickly remove enamel. In addition, incorrectly using end-cutting discs is a leading cause of enamel gouging and ledges. Take care to avoid inadvertently cutting the patient's tongue/lip or your finger/thumb.

A clear adaptor is advised to shield soft tissue from the disc and offers full visibility.

Discs can bind and jam in contacts if too much force is applied or an attempt is made to speed up IPR. This must be avoided and could result in the disc springing off.

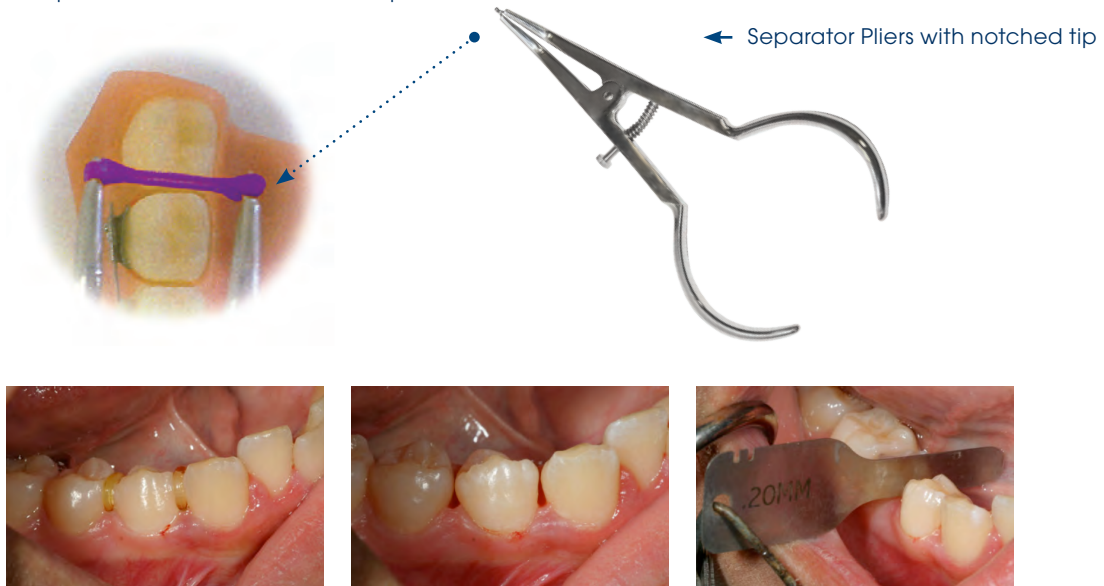


← Slow-speed handpiece, disc and clear adaptor

Note: Parallel contacts may be trimmed directly; for non-parallel teeth, separators MUST be used.

Step 1

First remove the separators using Separator Pliers or an explorer. Then, measure the amount of space present after removal of the separators using the IPR Gauge. The gauge size that gives a slight tug in the space indicates the size of the space.



↑ Separators in place for 1 week

↑ Remove the separators

↑ Measure the space created

Step 2

Add the measured amount of space created by the separators to the amount of reduction indicated on the treatment plan for the first phase of IPR. The total amount is the amount that needs to be present at the end of this visit.

For instance:

Total space created by separators = 2 mm

Space required from IPR phase 1 of treatment plan = 2 mm

Total space present at end of phase 1 IPR appointment needs to equal 4 mm

Note: The 2 mm gained by wearing the separators for 1 week is created to make IPR instrumentation easier. The separator-induced space closes rapidly, therefore this amount must NOT be included as 'gained space' for the treatment plan.

Step 3

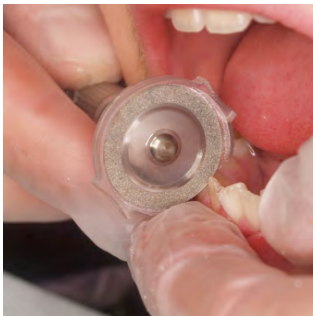
Initiate IPR using a disc of the smallest width to avoid binding. Single-sided discs are recommended to control IPR and avoid over-slenderizing adjacent teeth or introducing contouring errors.

Using a disc that only has abrasive on the outer area of the disc helps to preserve enamel.

Caution: Only use discs with a guard fitted over them to avoid cutting oral soft tissue or your thumb/fingers while performing IPR.

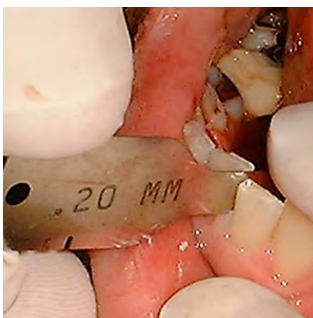A single-sided disc should be used on one tooth surface, and then the opposite single-sided disc (right or left) for the adjacent surface on the neighboring tooth, and always in accordance with the treatment plan regarding where the space should be created.

Caution: Only use the first disc that creates resistance until it no longer does, then measure the space before proceeding further to avoid creating excess space.



← Using the disc and clear adaptor

Step 4



← Measure the space created using the IPR Gauge following IPR performed with a disc

Step 5

Repeat Steps 4 & 5 with successive discs until the planned space has been created (or total of the separator-induced and planned space, if separators were used).

Step 6

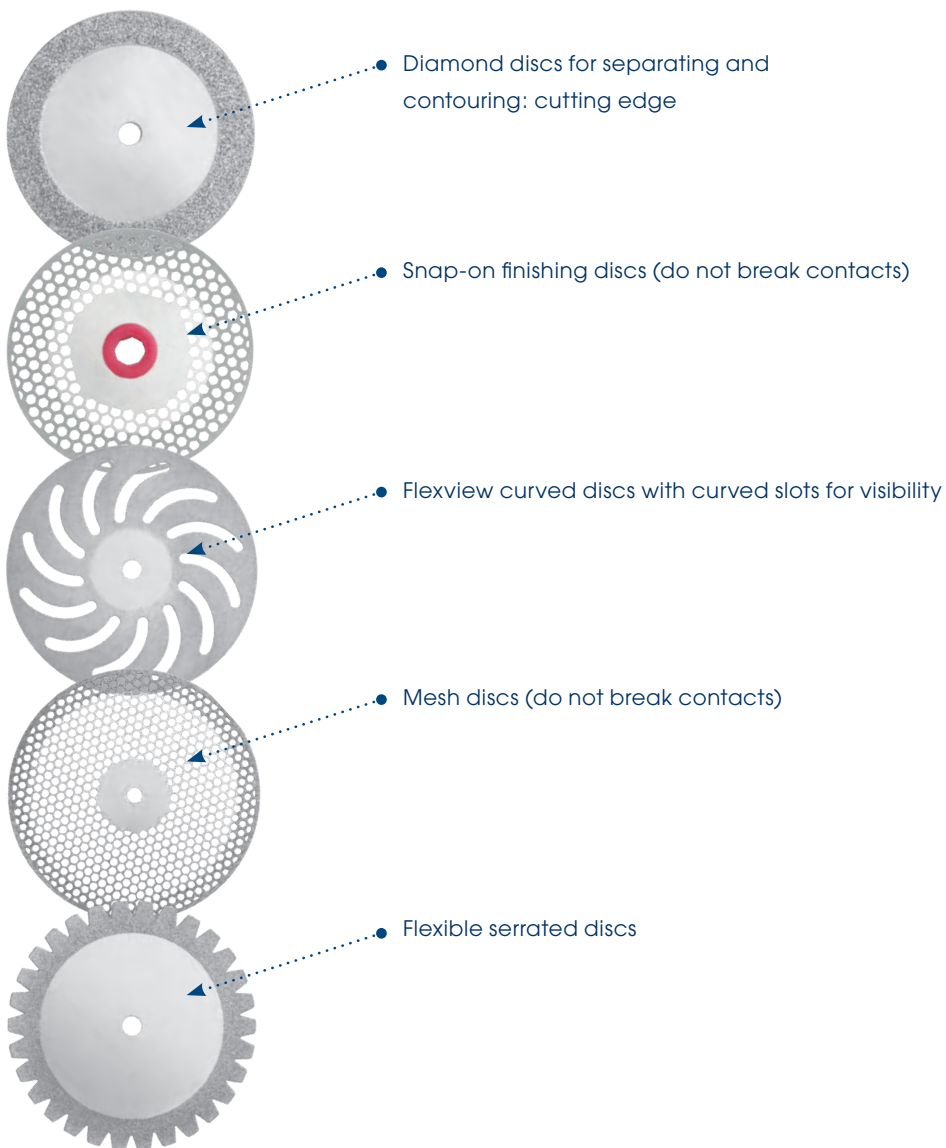
Use a finishing/recontouring disc that is non-end-cutting to precisely complete enamel reduction. Using a perforated disc improves visibility and reduces clogging.

Step 7

Use perforated finishing and polishing strips to smoothe the enamel surface, create the final contour and polish the enamel. Check for smoothness using an interproximal plastic strip and dental floss.



Disc Options



High-Speed Handpiece with Burs

This is mainly used for moderate crowding cases.


IPR burs and high-speed handpieces offer specific advantages over manual instrumentation:

- More rapid enamel reduction, especially relevant where full-mouth IPR is required
- Improved access posteriorly
- Patient comfort, although 'drilling' may negate this

Required Tools and Supplies

- Separators, and separator pliers or floss for placement
- IPR Gauge Set
- High-speed handpiece
- Bur kit – regular and safe-tipped burs
- Bur block
- Finishing and polishing files and grip

Bur block holding burs →



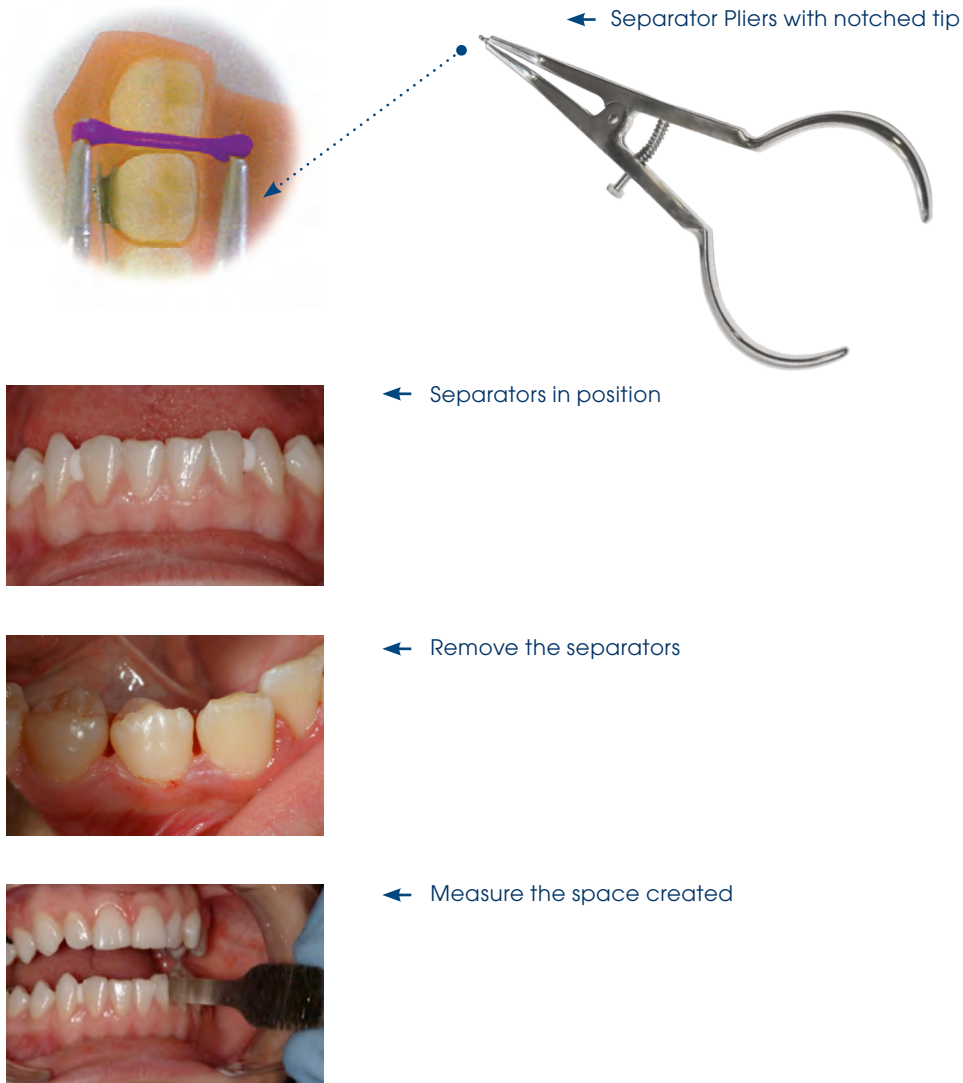
Caution: Burs can notch, gouge or create ledges in the enamel. Using a safe-tipped bur is preferable to using a standard bur to help prevent this from occurring. Note that only handheld strips are recommended to break contacts with overlapping teeth to avoid damage to enamel.

Step-By-Step: Cosmetic Tooth Recontouring [ARS]

If there is not already a space present at the starting point of the reduction sequence, a temporary space must be created so that proper access and visibility are available to perform the reduction. An orthodontic separator should be placed at the interproximal location deemed as the beginning re-contouring location. For posterior teeth, the separator should be present for one week. For anterior teeth, the separator should be in place for 2-4 days.

Step 1

After separators have been in place for the appropriate time, remove only one of them (if more than one was used). Removal is easily performed with an explorer or Separator Pliers. A clear visual pathway should be apparent as well as a blunted papilla. Using the leaf gauges, measure the amount of interproximal space created from the separator. This is a temporary space and should not be considered as useable for the purpose of moving teeth. The proper gauge will exhibit a slight tug as it passes through the space.

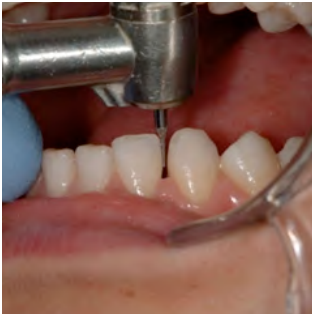

Step 2

If the starting location is on a cuspid or a posterior tooth, and the maximum amount of reduction is needed, then the clinician will add a 0.5 mm leaf gauge to the initial measurement, and this will be the target measurement for reduction of that proximal surface.

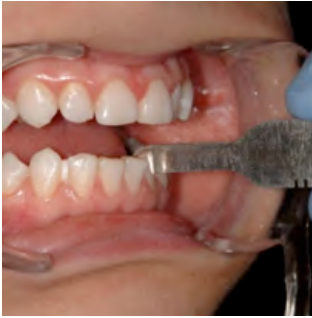If the starting point is on an incisor, a 0.25 mm leaf gauge will be added to the initial measurement, and becomes the target measurement for reduction of that proximal surface.

Step 3



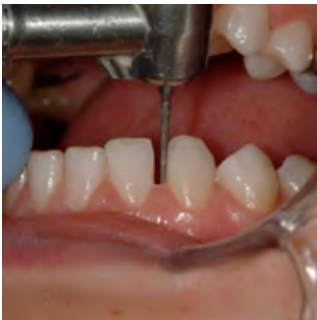Place the Anterior cross-cut carbide stripping bur in the handpiece and begin using gentle sweeping motions back and forth against the first proximal surface. In this case, it is the distal of #23 where 0.25 mm of enamel will be removed.

Orient the handpiece in such a manner that the flattened area created by the bur is vertical and not divergent toward the occlusal or incisal aspect of the tooth.



Stop periodically and measure the new space with the leaf gauges. Continue reduction of that surface until the two gauges representing the target measurement fit in the space.

Step 4



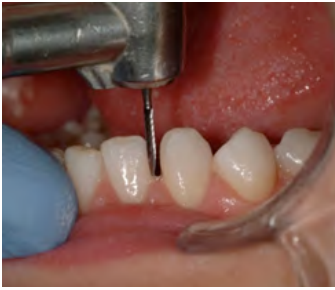↑
Using the larger diamond bur

Once the intended amount of enamel has been removed from one proximal surface, the adjacent proximal surface will be addressed. For this case a 0.5 mm leaf gauge will be added to the previous two gauges and the mesial surface of #22 will be reduced.

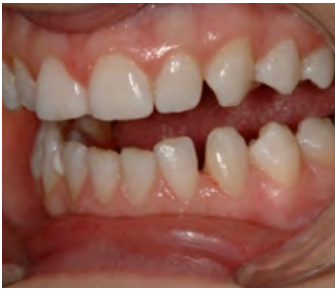Using the medium diamond finishing bur, re-orient the handpiece so that the new cut surface is parallel to the previously cut surface. This larger bur should not be in contact with the previously reduced surface. If there is not adequate clearance, use the anterior cross-cut carbide stripping bur until adequate clearance exists for the larger bur. Using gently sweeping motions, the adjacent proximal surface is reduced. Periodically stop and measure the new space with the leaf gauges. This is continued until the final amount of reduction is created.

The reduction is now complete and the opposing tooth surfaces should be parallel. The handpiece and diamond bur are now used to recontour and shape the buccal, lingual and incisal/occlusal embrasures. The final shape of the teeth should mimic what the original shape was prior to the interproximal reduction.

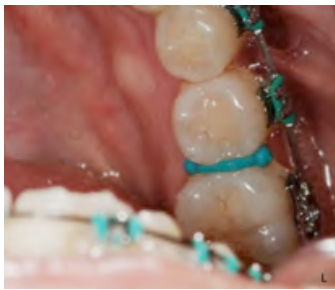Step 5



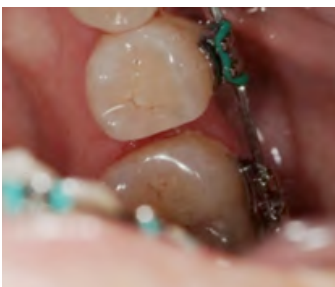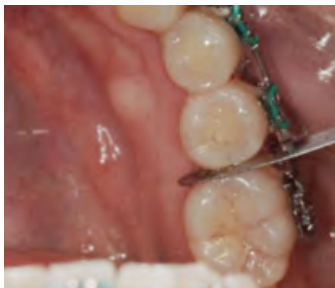A carbide finishing bur is now used to gently polish the enamel surfaces and remove the scratches using gentle sweeping hand movements.



If a man-made material was re-contoured, use the appropriate polisher necessary to achieve the same result as with the enamel technique. If there are other separators in the mouth, complete the steps above starting with the removal of each separator. The dates and location of the interproximal reduction are recorded on the ARS prescription sheet in the patient's chart.



For patients who are in fixed orthodontic appliances, the CTR protocol is the same. It is not always necessary to remove the archwire during the CTR procedure.



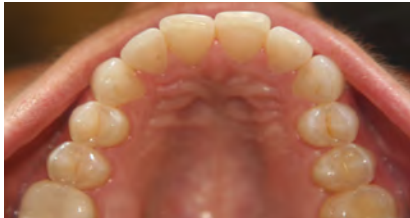Bur Options

DIAMOND-ANTERIOR	Head Size	Head Length	Max Speed
	1.5 mm	5 mm	<300,000 rpm
STANDARD TIP-POSTERIOR	Head Size	Head Length	Max Speed
	0.9 mm	5.2 mm	300,000 rpm
SAFE-TIPPED FINISHING BURS	Head Size	Head Length	Max Speed
 <i>Medium</i>	1.4 mm	10 mm	<450,000 rpm
 <i>Fine</i>	1.2 mm	8 mm	300,000 rpm
 <i>Extra Fine</i>	1.2 mm	10 mm	300,000 rpm
STANDARD-TIPPED FINISHING BURS	Head Size	Head Length	Max Speed
 <i>Medium</i>	1.2 mm	10 mm	<450,000 rpm
 <i>Fine</i>	0.9 mm	3 mm	<40,000 rpm
 <i>Extra Fine</i>	0.9 mm	3 mm	<30,000 rpm
 <i>Fine</i>	1.4 mm	10 mm	<40,000 rpm

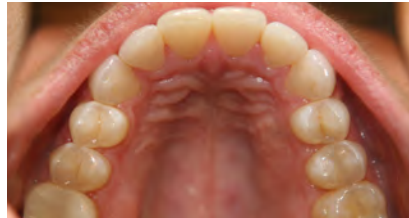

Cases & Tips For Success

Cases:

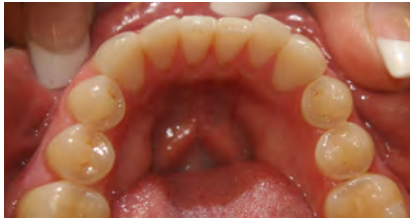

Before Treatment

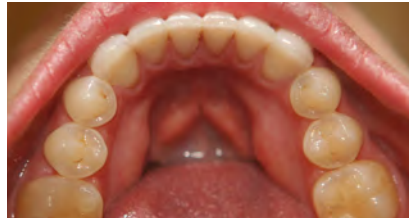

During Treatment

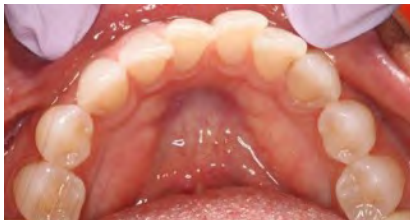Photos Courtesy of:
Dr. Ray Padilla



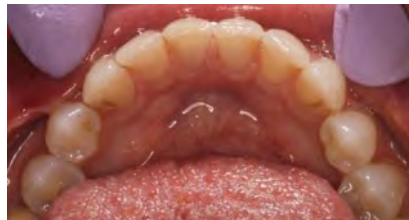Before Treatment



During Treatment

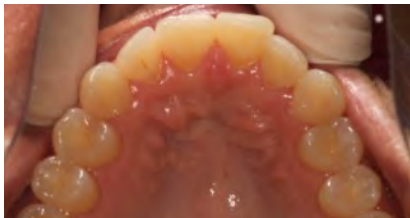

Before Treatment

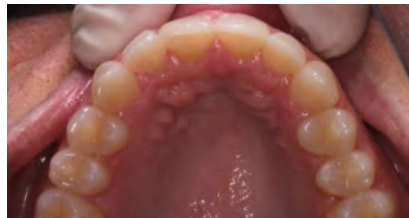

During Treatment

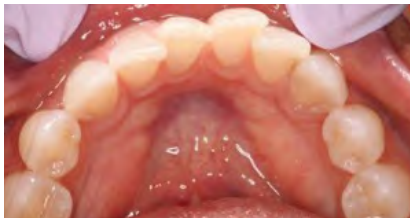Photos Courtesy of:
Dr. Lori Trost



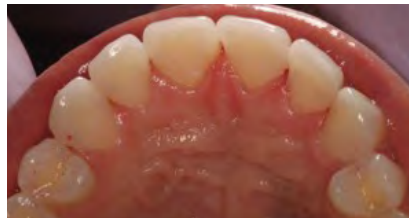Before Treatment



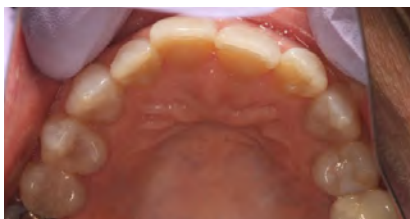During Treatment



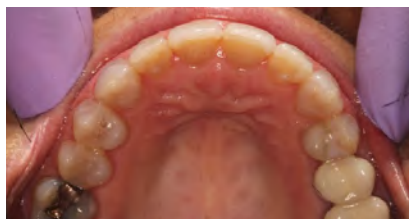Before Treatment



During Treatment

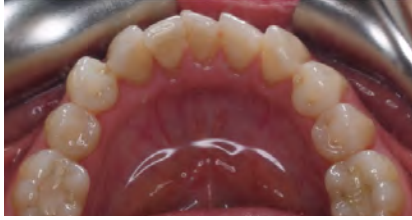

Before Treatment

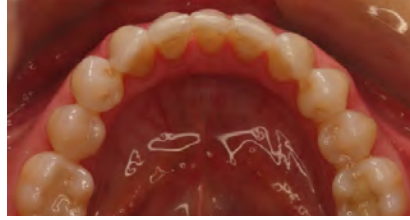

During Treatment

Cases

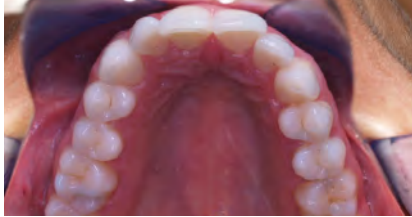

Before Treatment

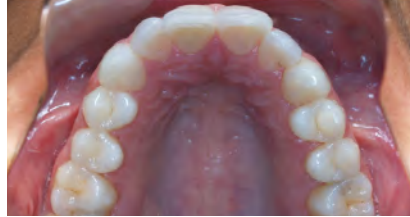

During Treatment

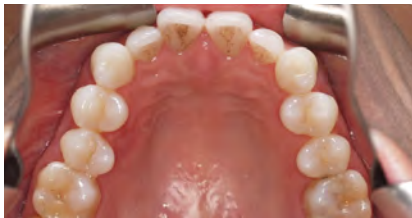Photos Courtesy of:
Dr. Neil Warshawsky



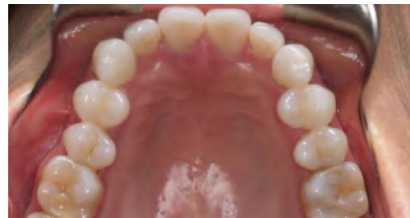Before Treatment



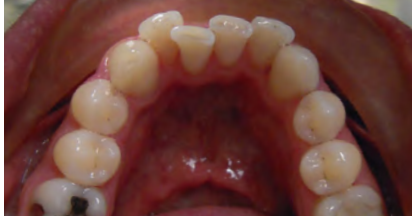During Treatment



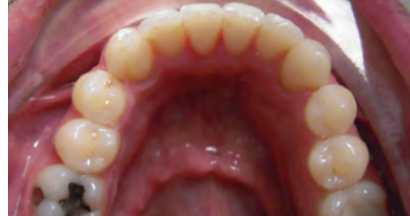Before Treatment



During Treatment

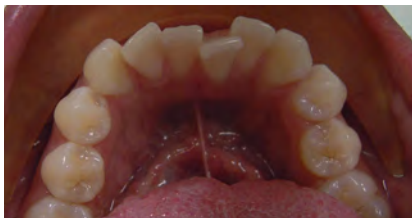

Before Treatment

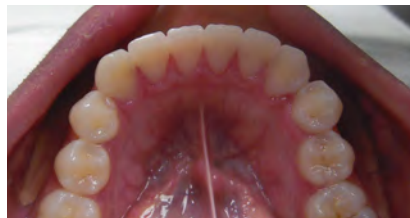

During Treatment

Photos Courtesy of:
Dr. David Galler



Before Treatment



During Treatment

Tips For Success

Tips for Successful IPR Treatment Planning

- Make sure to note in the patient's chart where IP was performed (which teeth and how much)
- Recommended total maximum amount of enamel reduction is 0.5 mm for incisors
- Only 0.5 mm of enamel per posterior proximal surface should be removed
- Staged IPR is especially helpful where contact points are inaccessible in the early phase of treatment due to their axial inclination. Access is easier once these are straightened.
- Single-sided reduction of one proximal surface at a time results in the most accurate reduction
- Rectangular teeth have wide contact points, that are less likely to show black triangles after IPR
- Avoid performing IPR on triangular-shaped teeth when possible as this can create black triangles
- Avoid performing IPR on non-parallel surfaces
- Performing IPR on barrel-shaped teeth can result in favorable repositioning with closer contact of adjacent teeth at the incisal edges

Tips for Successful IPR Execution

- Slenderizing 4.5 mm to 5 mm from the upper margin of the bone crest results in an interproximal contact point that helps to avoid the creation of "black triangles" that would mar esthetics
- Use separators to create temporary space prior to performing IPR
- Use a serrated contact point saw to open the contact point when performing IPR manually (this avoids files becoming stuck in the contact point)
- Use safe-tipped burs to prevent notching of enamel during ARS
- Perforated discs improve visibility compared to solid discs
- Use discs with a non-cutting edge to help preserve enamel
- An ARS Space Gauge may be used instead of an IPR Gauge and doubles as a perio probe
- The IPR Gauge that 'catches' in the space is the one that give the space measurement
- Protect the patient's tongue, lips and gingiva at all times
- Eye protection is recommended for patients and operators



Glossary of Terms

<u>Air Rotor Stripping</u>	Interproximal reduction performed with a high-speed air-driven handpiece and burs
<u>Bolton Analysis</u>	A method for assessing tooth size discrepancy, either using the Cuspid-to-Cuspid Bolton Index (canine to canine inclusive in an arch) or using the First-Molar-to-First Molar Bolton Index (first molar to first molar, inclusive, in an arch)
<u>Bone Crest</u>	The outer border of the alveolar bone measured at its highest point interproximally
<u>Bone Sounding</u>	The use of a periodontal probe to assess the height of the upper margin of the bone crest. Bone sounding is performed to determine the distance from the upper margin to the contact point of a given tooth.
<u>Burs for IPR</u>	Rotary cutting instruments used in IPR with a high-speed handpiece
<u>Crown-Root Ratio</u>	Physical relationship between the crown and the root; the ratio of the length of the part of a tooth that appears above the alveolar bone versus what lies below it
<u>Curve of Spee</u>	The anteroposterior curve determined by the occlusal alignment of the teeth
<u>Discs</u>	Discs are attached to a handpiece by a mandrel, in this case for use in a slow-speed straight handpiece for IPR
<u>Distalization</u>	Orthodontic movement of teeth in a distal direction, towards the back of the arch
<u>Elastomeric Separators</u>	Small hollow rings/ovoid shapes with elastic properties that can be inserted between adjacent teeth, prior to IPR to create space after the separators have been removed.
<u>Enamel Ledges</u>	Horizontal ledge-like defects that are created in the proximal wall of enamel as a result of incorrect placement of discs or burs while performing IPR. These can be avoided by using instruments that are not end-cutting and by performing IPR along the long axis of the enamel.

<u>Files</u>	Manual or mechanical metal strips used to perform IPR
<u>Force Points</u>	The points created in the aligner that push against specific teeth in a planned manner to produce directional movement of the teeth
<u>Iatrogenic</u>	An adverse condition caused by the treating clinician (e.g., enamel ledges created during IPR)
<u>Interarch Relationship</u>	The positioning/relationship of the maxilla with the mandible when in occlusion
<u>Interproximal Reduction (IPR)</u>	The process by which enamel (or restorative material) is removed from the mesial or distal surface of the tooth to create space that allows for planned orthodontic movement
<u>IPR Gauge</u>	A measurement gauge that consists of several gauges of different sizes. Each gauge is a thin metal rectangle of a specific width. The gauge that just fits in the space created by IPR, without being loose or having to force it in, correctly identifies the amount of space present following IPR. This gauge is also used to measure temporary space created by the use of elastomeric separators.
<u>Proclination</u>	The process by which anterior teeth are moved on an axis, moving the incisal edges in a labial, outward direction
<u>Rapid Palatal Expansion</u>	The process by which the maxillary arch is widened by widening the palate. This is typically performed using an appliance with a horizontal screw device that is turned a quarter-turn on a regular basis to induce rapid expansion of the width of the palate.
<u>Retroclination</u>	The process by which anterior teeth are move on an axis, moving the incisal edges in a lingual, inward direction

Social Six

The six anterior teeth in the upper or lower arch. These are referred to as the social six because these are the teeth involved in smiling, a social activity.

Torque

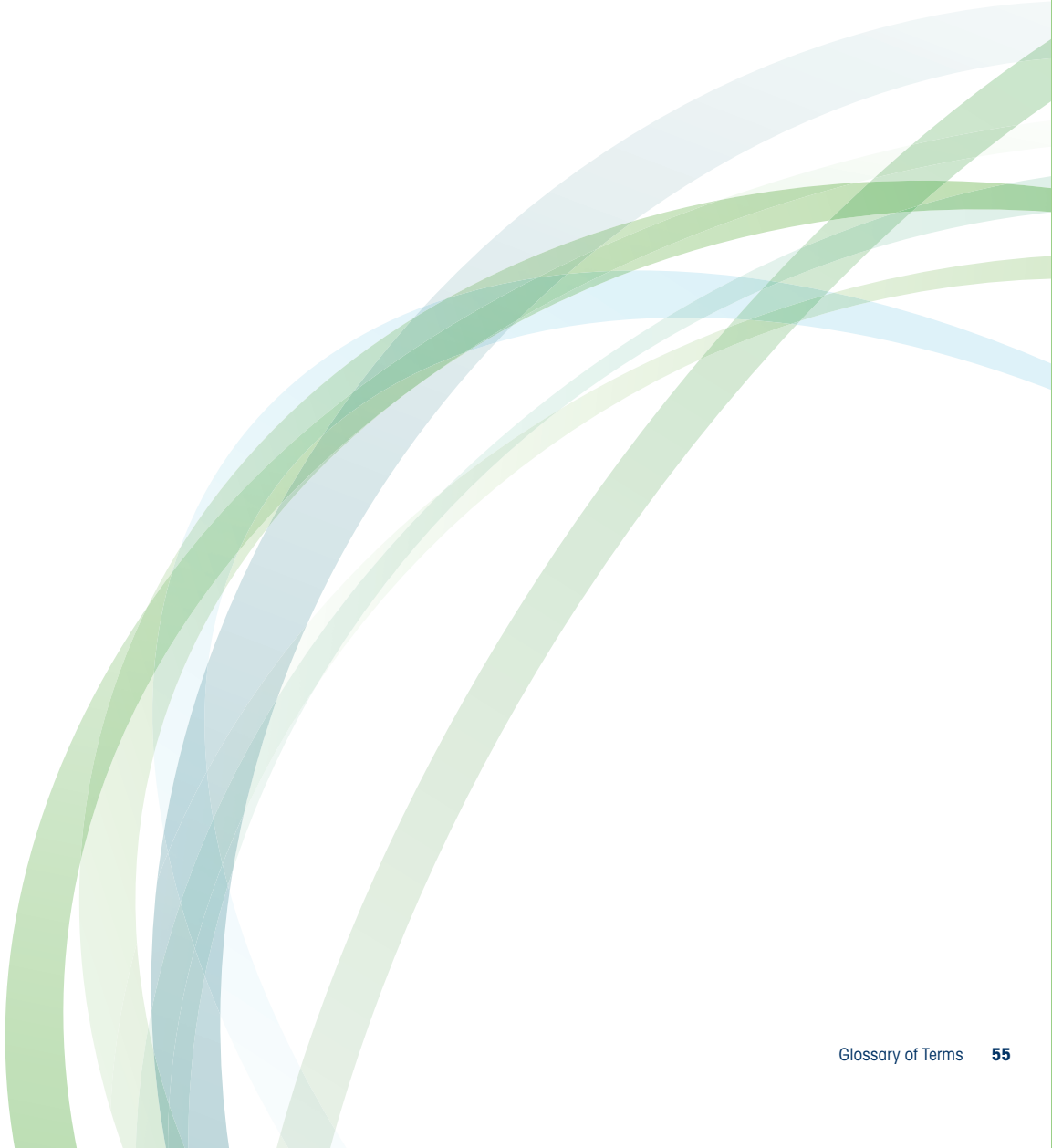Relative crown and root inclination perpendicular to the line of occlusion, for example lingual crown torque is same as labial root torque and labial root torque is the same as lingual root torque

Torquing

Application of a force that produces rotation (or torsion)

Vertex of the Papilla

The position of the most coronal point of the gingival papilla between two teeth. The contact point of the teeth should be aligned in a vertical line with the vertex of the papilla.





References & Acknowledgments

References

- Ballard ML. Asymmetry in tooth size: A factor in the etiology, diagnosis, and treatment of malocclusion. *Angle Orthod.* 1944;14:67-71.
- Bolton WA. Disharmony in tooth size and its relation to the analysis and treatment of malocclusion. *Angle Orthod.* 1958;28:113-130.
- Brudevold F, Tehrani A, Bakhos Y. Intraoral remineralization of abraded enamel. *J Dent Res.* 1982;65:456-59.
- Crain G, Sheridan JJ. Susceptibility to caries and periodontal disease after posterior air-rotor stripping. *J Clin Orthod.* 24:84-85.
- El-Mangoury NH, Moussa M, Mostafa Y, Girgis A. In vivo remineralization after air-rotor stripping. *J Clin Orthod.* 1991;25:75-78.
- Fillion D. Apport de la sculpture amelaire interproximale a l'orthodontie de l'adulte (premiere partie). *Rev Orthop Dentofacial.* 1992;26:279-93.
- Hanachi F. The demineralization and remineralization potential of stripped enamel surfaces. Thesis, Department of Ortho, Louisiana State University School of Dentistry, 1992.
- Hudson AL. A study of the effects of mesiodistal reduction of mandibular anterior teeth. *J Dent Res.* 1956;43:615-24.
- Kelsten LB. A technique for realignment and stripping of crowded lower incisors. *J Pract Orthod.* 1969;3:82-4.
- Kurth JR, Kokich VG. Open gingival embrasures after orthodontic treatment in adults. *Am J Orthod Dentofacial Orthop.* 2001;120:116-23.
- Othman SA, Harfradine NWT. Tooth-size discrepancy and Bolton's ratios: A literature review. *J Orthod.* 2006;33(2):45-51.
- Sheridan JJ. Air-rotor stripping. *J Clin Orthod.* 1985;19:43-59.
- Stroud JL, English J, Buschang PH. Enamel thickness of the posterior dentition: Its implications for nonextraction treatment. *Angle Orthod.* 1998;68:141-45.
- Tarnow DP, Magmer AW, Fletcher P. The effect of the distance from the contact point to the crest of the bone on the presence or absences of the interproximal dental papilla. *J Periodontol.* 1991;63:995-6.
- Zachrisson BU, Nuoygaard L, Mobarak K. Dental health assessed more than 10 years after interproximal enamel reduction of mandibular anterior teeth. *Am J Orthod Dentofacial Orthop.* 2007;131:162-9.

Acknowledgements

DENTSPLY Raintree Essix would like to thank Dr. David Galler, Dr. Jaimee Morgan, Dr. Stan Presley, Dr. Deborah Ruddell, Dr. Lori Trost and Dr. Neil Warshawsky, and to thank the editor of this technical guide, Dr. Fiona Collins.





DENTSPLY
RAINTREE ESSIX

1.800.883.8733 • essix.com
©2015 DENTSPLY RTE-104-15 Issued 07/15